ORIGINAL ARTICLE

# The Presentation and Management of Laryngeal Cleft

## *A 10-Year Experience*

*Reza Rahbar, DMD, MD; Isabelle Rouillon, MD; Gilles Roger, MD; Aaron Lin, MD; Roger C. Nuss, MD; Francoise Denoyelle, MD, PhD; Trevor J. McGill, MD; Gerald B. Healy, MD; Erea-Noel Garabedian, MD*

**Objective:** To review the presentation and associated congenital abnormalities of laryngeal cleft and present guidelines for its evaluation and management.

**Design:** A 10-year retrospective study (1994-2004) with institutional review board approval.

**Setting:** Two pediatric tertiary care medical centers.

**Patients:** Twenty-two pediatric patients (mean age, 21 months) with laryngeal cleft.

**Intervention:** Surgical repair of laryngeal cleft.

**Main Outcome Measures:** Sex, age, symptoms, other associated abnormalities, method of evaluation, type of laryngeal cleft, method of surgical repair, treatment outcome, complications, and long-term follow-up.

**Results:** All 22 patients underwent surgical repair for laryngeal cleft. Airway endoscopy confirmed the following types of laryngeal clefts: type 1 (n=3), type 2 (n=10), and type 3 (n=9). Surgical repair techniques included an open approach with or without interposition graft (n=16) and an endoscopic approach (n=6).

**Conclusions:** Early diagnosis and proper repair of laryngeal cleft are essential to prevent pulmonary damage and associated morbidity. Each patient should be assessed properly, and the surgical approach should be individualized based on the symptoms, other associated findings on airway endoscopy, and type of cleft.

*Arch Otolaryngol Head Neck Surg. 2006;132:1335-1341*

LARYNGEAL CLEFT IS A RARE condition. Symptoms range from mild stridor to massive aspiration and respiratory distress, depending on severity of the cleft. Diagnosis requires a high index of suspicion, accurate interpretation of preoperative studies, and thorough endoscopic evaluation. Different surgical approaches have been proposed for the management of laryngeal cleft. The purpose of this study is to present our experience with patients with laryngeal cleft and provide guidelines for its evaluation and management.

*CME course available at www.archoto.com*

**Author Affiliations:** Department of Otolaryngology, Children's Hospital (Drs Rahbar, Nuss, McGill, and Healy), and Department of Otology and Laryngology (Drs Rahbar, Lin, Nuss, McGill, and Healy), Harvard Medical School, Boston, Mass; and Department of Otolaryngology, Armand-Trousseau Children's Hospital, Paris, France (Drs Rouillon, Roger, Denoyelle, and Garabedian).

## METHODS

Patients treated for laryngeal cleft between 1994 and 2004 at Children's Hospital, Boston, Mass (n=7), and Armand-Trousseau Children's Hospital, Paris, France (n=15) were identified (**Table 1** and **Table 2**). A systematic medical chart review was undertaken to determine the age at the time of presentation, sex, symptoms, significant medical and family history, evaluation findings, initial treatment, need for subsequent treatments, efficacy of each treatment, and complications. We classified the type of laryngeal cleft in our patients based on the Benjamin and Inglis[1] classification system (**Figures 1**, **2**, and **3**A).

## RESULTS

Twenty-two patients were diagnosed as having laryngeal cleft (Table 1 and Table 2). Age at the time of diagnosis ranged from 15 days to 12 years (mean age, 21 months). Initial presentations were for airway difficulty (n=6), feeding difficulty (n=2), or a combination of both (n=14). Fifteen patients (68%) presented with another significant medical problem. Fourteen patients (64%) required other surgical interventions.


Downloaded from www.archoto.com at Harvard University Library, on February 2, 2007
©2006 American Medical Association. All rights reserved.

**Table 1. Preoperative Patient Characteristics**

| Patient No./ Sex/Age | Symptoms at Presentation | Medical History | Significant Surgical History | Swallow Studies Showing Aspiration, No. | Type of Cleft* | Other Significant Findings on Endoscopy |
|---|---|---|---|---|---|---|
| 1/F/12 y | Aspiration; recurrent pneumonia | Vater syndrome | Repair TEF | 2 | 1 | Left vocal cord paralysis |
| 2/M/6 y | Aspiration; stridor | Asperger syndrome | None | 1 | 1 | None |
| 3/F/3 y | Aspiration; recurrent pneumonia | None | Gastrostomy tube placement | 2 | 1 | None |
| 4/M/2 y | Aspiration; recurrent pneumonia | IgA deficiency | Gastrostomy tube placement | 10 | 2 | None |
| 5/F/3 y | Aspiration; feeding difficulty | Mild bronchopulmonary dysplasia; GER | Nissen fundoplication; gastrostomy tube placement | 6 | 2 | None |
| 6/M/1 mo | Respiratory distress | None | Gastrostomy tube placement | 3 | 3 | None |
| 7/M/5 y | Stridor | Opitz-Frias syndrome | Tracheotomy | 5 | 2 | None |
| 8/M/1 mo | Cyanotic attacks; feeding difficulty | Prematurity; GER; esophageal atresia | Esophagoplasty | 3 | 3 (3 rings) | Tracheobronchomalacia |
| 9/F/14 mo | Stridor; recurrent pneumonia; aspiration | Pallister-Hall syndrome | None | No study obtained | 3 (4 rings) | Tracheobronchomalacia |
| 10/F/13 mo | Stridor; recurrent pneumonia; aspiration | None | None | No study obtained | 3 (2 rings) | Tracheobronchomalacia |
| 11/M/12 mo | Feeding difficulty | TEF GER | Repair of TEF, tracheotomy; gastrostomy tube placement; Nissen fundoplication | 1 | 2 | Tracheobronchomalacia |
| 12/F/10 mo | Respiratory distress | GER | Nissen duplication; gastrostomy tube placement | 1 | 3 (4 rings) | Tracheobronchomalacia |
| 13/M/4 mo | Malnutrition; feeding difficulty; stridor | Esophageal atresia | Repair of esophageal atresia (esophagoplasty) | 1 | 3 (4 rings) | None |
| 14/M/1 mo | Recurrent pneumonia | Opitz-Frias syndrome; GER | Tracheotomy; gastrostomy tube placement Nissen duplication | 1 | 3 (4 rings) | None |
| 15/F/3 mo | Stridor | None | None | 1 | 2 | None |
| 16/M/15 d | Cyanotic attacks; feeding difficulty | Cleft lip; GER | Tracheotomy; gastrostomy tube placement; Nissen duplication | No study obtained | 3 (6 rings) | Tracheobronchomalacia |
| 17/F/7 mo | Feeding difficulty; recurrent pneumonia | Esophageal atresia | Esophagoplasty gastrostomy tube placement | 1 | 2 | Left vocal cord paralysis |
| 18/F/1 mo | Feeding difficulty; stridor; respiratory distress | None | None | No study obtained | 2 | Tracheobronchomalacia |
| 19/M/7 mo | Respiratory distress | None | Tracheotomy | No study obtained | 3 (2 rings) | Tracheobronchomalacia |
| 20/M/2 mo | Feeding difficulty; recurrent pneumonia | None | None | 1 | 2 | None |
| 21/F/8 mo | Stridor; recurrent pneumonia; aspiration | Rubella embryofetopathy (deafness, cataract, microphthalmia) | None | No study obtained | 2 | Laryngomalacia Glossoptosis |
| 22/F/1 mo | Feeding difficulty | Cleft palate | None | 1 | 2 | None |

Abbreviations: GER, gastroesophageal reflux; TEF, tracheoesophageal fistula.
*Based on the Benjamin and Inglis[1] classification system.

Methods of evaluation included rigid airway endoscopy (n=22), esophagoscopy (n=16), and preoperative modified swallow study (n=16). Airway endoscopy confirmed laryngeal cleft in all patients: type 1 (n=3), type 2 (n=10), and type 3 (n=9). Other significant findings noted at the time of endoscopy included tracheobronchomalacia (n=8), unilateral vocal cord paralysis (n=2), laryngomalacia (n=1), and glossoptosis (n=1).

All patients were managed medically for gastroesophageal reflux (GER) during the perioperative and postoperative periods. Five patients underwent a combination of Nissen fundoplication and gastrostomy tube placement, and 4 patients required gastrostomy tube placement alone. The mean age at the time of laryngeal cleft repair was 21 months. All patients with type 1 laryngeal cleft underwent an initial trial of con-


Downloaded from www.archoto.com at Harvard University Library, on February 2, 2007
©2006 American Medical Association. All rights reserved.

**Table 2. Perioperative and Postoperative Patient Characteristics**

| Patient/ Sex/Age | Age at the Time of Surgery | Repair Approach | Postoperative Duration of Intubation | Postoperative Swallow Study Findings | Complications | Duration of Follow-up |
|---|---|---|---|---|---|---|
| 1/F/12 y | 12 y | Endoscopic | 1 d | Normal | None | 1 y |
| 2/M/6 y | 6 y | Endoscopic | 1 d | Normal | None | 2 y |
| 3/F/3 y | 3 y | Endoscopic | 1 d | Normal | None | 10 mo |
| 4/M/2 y | 2 y | Endoscopic | 1 d | Normal | None | 15 mo |
| 5/F/3 y | 3 y | Endoscopic | 3 d | First MSS showed aspiration; second study showed no aspiration | Pneumonia | 12 mo |
| 6/M/1 mo | 4 mo | Endoscopic | 4 d | Normal | None | 17 mo |
| 7/M/5 y | 5 y | Open, with interposition tibial periosteum graft | Preexisting tracheotomy tube in place | Normal | None | 5 y |
| 8/M/1 mo | 2 m | Open, with interposition tibial periosteum graft | 8 d | First MSS showed aspiration; second study showed no aspiration | None | 7 y |
| 9/F/14 mo | 14 mo | Open, with interposition tibial periosteum graft | 6 d | None | None | 8 y |
| 10/F/13 mo | 13 mo | Open, with interposition tibial periosteum graft | 4 d | None | None | 8 y |
| 11/M/12 mo | 12 mo | Open, with interposition tibial periosteum graft | 8 d | None | None | 5 y |
| 12/F/10 mo | 11 mo | Open, with interposition tibial periosteum graft | 12 d | Normal | Secondary surgery for residual communication | 2.5 y |
| 13/M/4 mo | 7 mo | Open, with interposition tibial periosteum graft | 8 d | Normal | Mild aspiration of thin liquid | 5 y |
| 14/M/1 mo | 2 mo | Open, with interposition tibial periosteum and auricular cartilage graft | Unknown | Normal | None | 14 mo |
| 15/F/3 mo | 5 mo | Open, with interposition tibial periosteum graft | 7 d | Normal | Subcutaneous emphysema postoperatively; thrombosis of the superficial femoral vein | 1.5 y |
| 16/M/15 d | 1 mo | Open, with interposition tibial periosteum graft | 7 d | None | Secondary surgery for loosening of the sutures at the upper part of the graft; tracheotomy due to subglottic edema and tracheomalacia | 2 y |
| 17/F/7 mo | 18 mo | Open, with interposition auricular cartilage graft | 4 d | Normal | Pneumonia | 1 y |
| 18/F/1 mo | 1 mo | Open, with interposition tibial periosteum graft | 8 d | Aspiration with liquids | Mild aspiration of thin liquid | 3.5 y |
| 19/M/7 mo | 7 mo | Open, with interposition tibial periosteum graft | 18 d | None | Tracheotomy due to significant subglottic edema and tracheomalacia | 6 y |
| 20/M/2 mo | 2 mo | Open, with interposition auricular cartilage graft | 6 d | None | None | 10 mo |
| 21/F/8 mo | 8 mo | Open, with no interposition | 4 d | None | None | 1 y |
| 22/F/1 mo | 1 mo | Open, with no interposition | 2 d | None | None | 2 y |

Abbreviation: MSS, modified swallow study.

servative monitoring with thickened feed. However, they continued to aspirate with thin liquid both clinically and on documented swallow studies.

Open reconstruction approach with or without interposition graft was used in 16 patients: interposition tibial periosteum graft (n=11), interposition auricular cartilage graft (n=2), a combination of these 2 grafts (n=1), and no interposition graft (n=2). Endoscopic approach for repair of laryngeal cleft was used in 6 patients: 3 with type 1 cleft, 2 with type 2, and 1 with type 3.

The duration of postoperative intubation ranged from 1 to 4 days (mean duration, 1.8 days) in the endoscopic group. Patients who underwent an open approach had a mean postoperative intubation period of 7.3 days (range, 2-18 days) in 14 cases, an unknown intubation period in 1 case, and a preexisting tracheotomy in 1 case, decannulated several months after repair of the laryngeal cleft.


Downloaded from www.archoto.com at Harvard University Library, on February 2, 2007
©2006 American Medical Association. All rights reserved.

**Figure 1.** Type 2 laryngeal cleft.

**Figure 2.** Type 3 laryngeal cleft.

Eight patients (36%) experienced a complication. Overall, complications included pneumonia (n=2), persistence of aspiration with thin liquid (n=2), secondary surgery owing to residual communication or loose sutures (n=2), subcutaneous emphysema and thrombosis of superficial femoral vein (n=1), and need for tracheotomy owing to subglottic edema and tracheomalacia (n=2). The duration of follow-up ranged from 10 months to 8 years (mean follow-up, 36 months) for the 22 patients.

## COMMENT

The incidence of laryngeal cleft is approximately 1 in 10 000 to 20 000 live births.[2] It is more common in boys than girls, with a ratio of 5:3.[3,4] The affect of prematurity and hydramnios as contributing factors remains controversial. A possible autosomal dominant pattern of inheritance has also been reported in some families.[3]

Embryologically, the trachea and esophagus share a common lumen until they are separated by the development of the tracheoesophageal septum. Failure of this fusion and incomplete development of the tracheoesophageal septum may lead to congenital abnormalities such as isolated laryngeal cleft, tracheoesophageal fistula, and esophageal atresia, depending on the severity of the abnormality.[5,6]

As Bell et al[7] report, the first patient with laryngeal cleft was described by Richter in 1792. In 1955, Pettersson[8] reported the first surgical repair of a type 1 laryngeal cleft. Several classification systems for laryngeal cleft have been introduced by different investigators: Cohen[9] in 1975, Armitage[10] in 1984, and Evans[11] in 1985. In 1989, Benjamin and Inglis[1] presented a classification system in which 4 types of cleft were described: type 1 is a supraglottic interarytenoid defect that extends inferiorly no further than the level of the true vocal folds; in type 2, the cricoid lamina is partially involved, with extension of the cleft below the level of the true vocal folds; type 3 is a total cricoid cleft that extends completely through the cricoid cartilage with or without further extension into the cervical trachea; and type 4 extends into the posterior wall of the thoracic trachea and may extend as far as the carina.

Any newborn with feeding problems, repeated aspiration, and respiratory distress should have a thorough evaluation. A complete prenatal and birth history must be taken. Congenital infections, maternal drug use, hypoxia, or birth trauma may cause temporary or permanent feeding difficulty. Other conditions such as esophageal stricture, tracheoesophageal fistula, cricopharyngeal spasm, neuromuscular abnormalities, laryngomalacia, GER, and vocal cord paralysis should be included in the differential diagnosis of these patients. It is essential to have a high index of suspicion for other associated abnormalities including gastrointestinal (16%-67%), genitourinary tract (14%-44%), and cardiovascular (16%-33%) that have been reported in patients with laryngeal cleft.[2,4,12] A higher incidence of laryngeal cleft is also reported with Pallister-Hall syndrome and Opitz-Frias syndrome.[12] Roth and colleagues[2] reviewed 85 well-documented cases of all subtypes of cleft and reported an overall mortality rate of 46% due to laryngeal cleft and associated congenital abnormalities.

Stridor, choking, cyanosis, and regurgitation are typical manifestations of laryngeal cleft or laryngotracheoesophageal cleft. Routine chest radiography might show pulmonary infiltrates secondary to aspiration. Modified swallow studies and fiberoptic endoscopic evaluations of swallowing are also helpful in evaluation of laryngeal cleft. However, it is often difficult to differentiate laryngeal incompetence and aspiration due to a laryngeal cleft vs neuromuscular incoordination. It is also important to realize that modified swallow studies and fiberoptic endoscopic evaluations of swallowing only document several cycles of swallowing and may produce normal results if the child is aspirating only intermittently. Flexible laryngoscopy gives a limited view of the posterior glottic space and should not be relied on to make the diagnosis.

Microlaryngoscopy under general anesthesia remains the gold standard in the diagnosis of laryngeal cleft. Laryngeal cleft may be obscured by redundant laryngeal and/or esophageal mucosa prolapsing into the cleft. Therefore, it is of paramount importance to examine the larynx carefully, and the arytenoids must be parted with a probe to make the correct diagnosis. We noted other significant associated findings in 50% of our patients at the time of endoscopy, which is similar to the findings in other


Downloaded from www.archoto.com at Harvard University Library, on February 2, 2007
©2006 American Medical Association. All rights reserved.

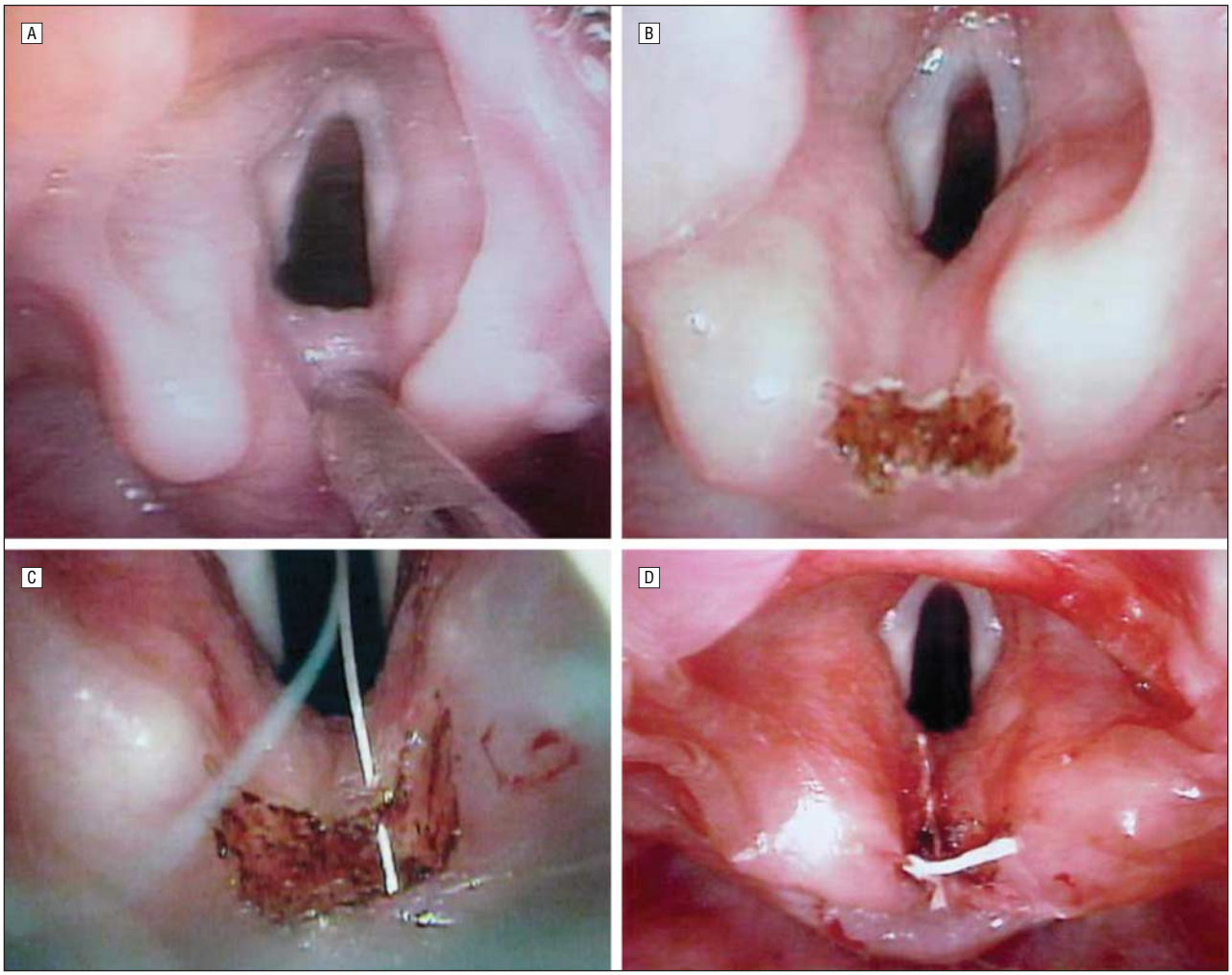


**Figure 3.** Endoscopic approach to repair a type 1 laryngeal cleft. A, Type 1 laryngeal cleft at presentation; B, after carbon-dioxide laser cut; C, first suture being placed in the deepest part of the cleft; D, closure of the cleft using endoscopic approach.

studies: Parsons et al,[13] 66%; Evans et al,[14] 65%; and Moungthong and Holinger,[15] 64%. One of the most common associated findings is tracheobronchomalacia.[16,17] We recommend performing the airway endoscopy with the patient breathing spontaneously and with no positive airway pressure to avoid masking the signs of airway collapse. The presence of tracheoesophageal fistula has also been reported in 20% to 37% of patients with laryngeal cleft.[6,14] Therefore, it is essential to perform a complete evaluation of tracheobronchial tree and esophagus under general anesthesia to rule out other associated abnormalities in all patients with laryngeal cleft.

The timing and approach for surgical repair depends on the severity of symptoms, associated abnormalities, and the type of cleft. In small clefts, the proper diagnosis might be missed, and the patient could survive into adult life with recurrent respiratory infections.[18,19] In the more extensive form, the condition may be fatal unless properly diagnosed and corrected surgically in a timely fashion. Some authors have advocated observation and expectant management of minor clefts using positioning and thickened food to prevent aspiration.[20,21] We believe early diagnosis and surgical repair of laryngeal cleft is important to reduce the irreversible pulmonary damage and other associated morbidities that may occur as a result of repeated aspiration.

In the past decades different operative approaches have been proposed for the management of laryngeal cleft. In 1967, According to Evans,[11] Jahrsdoerfer and colleagues described the anterior approach, which involves exposure of the cleft by means of thyrotomy, cricoidotomy, and tracheofissure to the first and second rings to provide direct access to the posterior cleft and allow for microsurgical closure. Some authors have advocated avoiding the anterior approach owing to possible risk of laryngeal instability and long-term laryngeal growth disturbances.[11,22] The lateral pharyngotomy approach has also been described as an approach that avoids the laryngofissure.[11] In our experience, and as reported by other investigators,[23] meticulous closure under magnification, proper stenting with a nasotracheal tube, and excellent postoperative care in the intensive care unit will limit the risk of laryngeal instability with the anterior approach. For a more extensive cleft involving the thoracic trachea, a lateral pharyngotomy with a right thoracotomy approach or an anterior approach with a median sternotomy has been used.[5,24]


Downloaded from www.archoto.com at Harvard University Library, on February 2, 2007
©2006 American Medical Association. All rights reserved.

One of the well-known complications of laryngeal cleft surgery is the risk of loosening and dehiscence of sutures at the site of cleft repair. Anastomotic leaks are reported to occur in approximately 50% of the repairs and generally require reoperation.[4] This can be due to a combination of factors such as laryngeal movement, GER, coughing, and pressure caused by an endotracheal tube or nasogastric tube.[25] Investigators have advocated the use of an interposition graft such as the sternocleidomastoid muscle,[26] costal cartilage,[27] and pleural flap[28] to decrease the risk of dehiscence. In 1998, Garabedian and colleagues[25] reported the use of tibial periosteum as an interposition graft. The theoretical advantages of this graft include a strong resistance to necrosis and its osteogenic properties. It also has the advantages of being thin, rigid, and easy to handle. The disadvantage of the tibial periosteal graft is the possibility of donor site morbidity.

Other complications of surgical repair include laryngeal nerve injury, granulation tissue formation, esophageal stricture, and continued aspiration. It has also been reported that some of the feeding issues may continue for a short period postoperatively, despite successful surgical repair of the cleft, due to neurological disturbance of the swallowing reflex.[23,25]

Six of our patients underwent an endoscopic approach for repair of laryngeal cleft. Endoscopic repair was performed using suspension microlaryngoscopy under general anesthesia with spontaneous breathing. The larynx was visualized with a Lindholm laryngoscope. A carbon dioxide laser at a setting of 3 W at 0.3-second intermittent mode was used to denude the mucosal margin of the cleft. It is of paramount importance to completely remove the mucosa at the apex of the cleft to prevent persistence of the fistula at the lower end of the repair.

Absorbable interrupted sutures (4-0 Vicryl; Ethicon Inc, Somerville, NJ) were used to close the cleft. The first suture is the most important and must be placed at the most inferior extent of the cleft. We generally place 3 to 4 sutures, depending on the extent of the cleft (Figure 3).

The success of the endoscopic approach depends on proper exposure of the cleft at the time of suspension laryngoscopy and magnification under microscope. In our experience, avoiding endotracheal intubation and maintaining general anesthesia under spontaneous breathing allow for much better exposure and increase the chances of success. Based on our experience, we advocate the minimally invasive endoscopic approach for types 1 and 2 clefts. We have repaired 1 case of type 3 in which the cleft extended through the cricoid but did not involve the tracheal rings with a good outcome. Our experience is very limited with the endoscopic repair of a type 3 cleft, and to our knowledge, no large series with long-term follow-up has been conducted. Based on our limited experience, the endoscopic approach for type 3 laryngeal cleft may be considered if there is no involvement of the tracheal rings.

Sixteen of our patients underwent the open approach for repair of the cleft. An interposition graft was used in 14 of these patients, as described by Garabedian and colleagues.[25] The harvesting of the tibial graft is a straightforward process and should be done on the anteromedial surface of the tibia to prevent any consequences on tibial growth.[25] It is also essential to secure the periosteal graft laterally to prevent it from moving and folding on itself.[25] An auricular cartilage graft or temporalis fascia can also be used as an interposition graft with good success. We advocate using the open approach with an interposition graft in patients who have type 2 clefts when adequate endoscopic exposure is limited or in the case of a more extensive cleft.

Regardless of surgical approach, a number of critically important factors should be addressed in the preoperative period. Gastroesophageal reflux must be evaluated and controlled with medical therapy and/or surgical intervention prior to repair of the cleft. We believe that Nissen fundoplication should be considered, especially in children with increased pharyngeal and tracheobronchial secretions and recurrent aspiration pneumonia. All patients should continue with anti-GER medication postoperatively and have a close follow-up to be sure the GER is under control.

The other issue is the degree of tracheomalacia and/or tracheobronchomalacia that is seen in these patients, which may cause further difficulty with airway symptoms and even prevent extubation despite proper surgical repair of the cleft. Even though the natural history of tracheomalacia is one of gradual improvement as the child grows, most of these patients may require intervention during the preoperative and postoperative periods. Treatment options include continuous positive airway pressure, stenting the airway by prolonged intubation, aortopexy, and tracheotomy. We do not advocate prolonged endotracheal stenting postoperatively owing to the risk of laceration and dehiscence of the cleft repair. Tracheotomy is a viable option for some of these patients despite known morbidity and mortality.

Based on our experience and reports by other investigators,[4,7,9,12] it is clear that the management of laryngeal cleft is challenging from both the medical and surgical standpoints. Different surgical options have been proposed, and no option is applicable to all patients. Each patient should be assessed properly, and a surgical approach should be individualized based on the symptoms, other associated findings on airway endoscopy, and the type of the cleft.

**Submitted for Publication:** June 28, 2005; final revision received May 18, 2006; accepted June 7, 2006.
**Correspondence:** Reza Rahbar, DMD, MD, Department of Otolaryngology, Children's Hospital, 300 Longwood Ave, Boston, MA 02115 (reza.rahbar@childrens.harvard.edu).
**Author Contributions:** Dr Rahbar had full access to all the data in the study and takes responsibility for the integrity of the data and the accuracy of the data analysis. *Study concept and design:* Rahbar, Lin, Nuss, McGill, and Healy. *Acquisition of data:* Rahbar, Rouillon, Roger, Denoyelle, and Garabedian. *Drafting of the manuscript:* Rahbar, Rouillon, and Denoyelle. *Critical revision of the manuscript for important intellectual content*: Rahbar, Roger, Lin,


Downloaded from www.archoto.com at Harvard University Library, on February 2, 2007
©2006 American Medical Association. All rights reserved.

Nuss, Denoyelle, McGill, Healy, and Garabedian. *Administrative, technical, and material support:* Rouillon. *Study supervision:* Rahbar, Roger, Lin, Nuss, Denoyelle, McGill, Healy, and Garabedian.
**Financial Disclosure:** None reported.
**Previous Presentation:** This article was presented at the American Society of Pediatric Otolaryngology meeting; May 2005; Las Vegas, Nev.

## REFERENCES

1. Benjamin B, Inglis A. Minor congenital laryngeal clefts: diagnosis and classification. *Ann Otol Rhinol Laryngol*. 1989;98:417-420.
2. Roth B, Rose KG, Benz-Bohm G, Gunther H. Laryngotracheoesophageal cleft: clinical features, diagnosis and therapy. *Eur J Pediatr*. 1983;140:41-46.
3. Phelan PD, Stocks JG, Williams HE, et al. Familial occurrence of congenital laryngeal clefts. *Arch Dis Child*. 1973;48:275-278.
4. DuBois JJ, Pokorny WJ, Harberg FJ, Smith RJH. Current management of laryngeal and laryngotracheoesophageal clefts. *J Pediatr Surg*. 1990;25:855-860.
5. Hast MH. The developmental anatomy of the larynx. *Otolaryngol Clin North Am*. 1970;3:413-438.
6. Lim TA, Spanter SS, Kohut RI. Laryngeal clefts: a histopathologic study and review. *Ann Otol Rhinol Laryngol*. 1979;88:837-845.
7. Bell DW, Christiansen TA, Smith TE Jr, Stucker FJ. Laryngotracheoesophageal cleft: the anterior approach. *Ann Otol Rhinol Laryngol*. 1977;86:616-622.
8. Pettersson G. Inhibited separation of the larynx and the upper part of the trachea from the esophagus in a newborn: report of a case successfully operated upon. *Acta Chir Scand*. 1955;110:250-254.
9. Cohen SR. Cleft larynx: a report of seven cases. *Ann Otol Rhinol Laryngol*. 1975; 84:747-756.
10. Armitage EN. Laryngotracheo-esophageal cleft. *Anaesthesia*. 1984;39:706-713.
11. Evans JG. Management of the cleft larynx and tracheoesophageal clefts. *Ann Otol Rhinol Laryngol*. 1985;94:627-630.
12. Tyler DC. Laryngeal cleft: report of eight patients and review of the literature. *Am J Med Genet*. 1985;21:61-78.
13. Parsons DS, Stivers FE, Giovanetto DR, Phillips SE. Type I posterior laryngeal clefts. *Laryngoscope*. 1998;108:403-410.
14. Evans KL, Courteney-Harris R, Bailey M, Evans JNG, Parsons DS. Management of posterior laryngeal and laryngotracheoesophageal clefts. *Arch Otolaryngol Head Neck Surg*. 1995;121:1380-1385.
15. Moungthong G, Holinger LD. Laryngotracheoesophageal clefts. *Ann Otol Rhinol Laryngol*. 1997;106:1002-1011.
16. Mitchell DB, Koltai P, Matthew D, Bailey CM, Evans JNG. Severe tracheobronchomalacia associated with laryngeal cleft. *Int J Pediatr Otorhinolaryngol*. 1989; 18:181-185.
17. Denneny JC. Bronchomalacia in the neonate. *Ann Otol Rhinol Laryngol*. 1985;94: 466-469.
18. Montgomery WW, Smith SA. Congenital laryngeal defects in the adult. *Ann Otol Rhinol Laryngol*. 1976;85:491-497.
19. Lancaster JL, Hanafi Z, Jackson SR. Adult presentation of tracheoesophageal fistula with co-existing laryngeal cleft. *J Laryngol Otol*. 1999;113:469-472.
20. Wolfson PJ, Schloss MD, Guttman FM, Nguyen L. Laryngotracheoesophageal cleft: an easily missed malformation. *Arch Surg*. 1984;119:228-230.
21. Glossop LP, Smith RJH, Evans JNG. Posterior laryngeal cleft: an analysis of ten cases. *Int J Pediatr Otorhinolaryngol*. 1984;7:133-143.
22. Donahoe PK, Gee PE. Complete laryngotracheoesophageal cleft: management and repair. *J Pediatr Surg*. 1984;19:143-148.
23. Froehlich P, Truy E, Stamm D, Morgan A, Floret D, Chappuis JP. Cleft larynx: management and one-stage surgical repair by anterior translaryngotracheal approach in two children. *Int J Pediatr Otorhinolaryngol*. 1993;27:73-78.
24. Cotton RT, Schreiber JT. Management of laryngotracheoesophageal cleft. *Ann Otol Rhinol Laryngol*. 1981;90:401-405.
25. Garabedian EN, Ducroz V, Roger G, Denoyelle F. Posterior laryngeal clefts: preliminary report of a new surgical procedure using tibial periosteum as an interposition graft. *Laryngoscope*. 1998;108:899-902.
26. Hendren WH. Repair of laryngotracheoesophageal cleft using interposition of a strap muscle. *J Pediatr Surg*. 1976;11:425-429.
27. Prescott CA. Cleft larynx: repair with a posterior cartilage graft. *Int J Pediatr Otorhinolaryngol*. 1995;31:91-94.
28. Pinlong E, Lesage V, Robert M, Mercier C, Ployet MJ. Type III-IV laryngotracheoesophageal cleft: report of a successfully treated case. *Int J Pediatr Otorhinolaryngol*. 1996;36:253-262.


Downloaded from www.archoto.com at Harvard University Library, on February 2, 2007
©2006 American Medical Association. All rights reserved.